



MSI Journal

of Medicine and Medical Research

(MSIJMMR)

Frequency:- Monthly Published by MSI Publishers

ISSN:- 3049-1401 (Online)

Journal Link:- <https://msipublishers.com/msijmmr/>

Volume:- 2, *Issue:-* 3 (March-2025)

Article History

Received on :- 16-03-2025

Accepted on :- 20-03-2025

Published on :- 27-03-2025

Total Page: - 13-21

DOI: [10.5281/zenodo.15092575](https://doi.org/10.5281/zenodo.15092575)

Knowledge About the Chemical Composition, Possible Therapies, Medications, and Treatment of Venoms from Colored Ants (Hymenoptera) and Beetles (Coleoptera)

By

Marco Vinícios de Oliveira Santana¹, Carlos Henrique Marchiori^{1*}, Klebert de Paula Malheiros¹, Êrico Meirelles de Melo¹

Researchers of Instituto Marco Santana, Goiânia, Goiás, Brazil^{1*}

Abstract: Ants, like other insects, communicate through pheromones, a chemical substance that provokes specific reactions between individuals of the same species. Thus, they can leave a chemical signal that serves as an alert or warning to other ants. One of the characteristics that make beetles so easy to recognize is their hardened sides, which serve as armor to protect the more delicate flight wings and the soft abdomen underneath. This manuscript aims to gain knowledge about the chemical composition, possible therapies, medications, and treatment of venoms from colored ants (Hymenoptera) and beetles (Coleoptera). This is a bibliographic review of the literature. The data collection was the result of searching databases of articles that gather information in English and Portuguese with: PubMed (<http://www.ncbi.nlm.nih.gov/pubmed>), STM (Science Translational Medicine, <https://stm.sciencemag.org>); and SciELO (Scientific Electronic Library Online, <http://www.scielo.org/php/-index.php>). In addition to the databases cited, Google Scholar was also used, in the English and Portuguese versions (<https://scholar.google.com> and <https://scholar.google.com.br/>).

Keywords: Anaphylactic, Biotechnology, Chemical substance, Piperidine, Predators

1.0. Introduction

Ants have complete organization, with a defined structure, each caste performs specific work in the colony, and they are highly social. In them, we can differentiate castes: explorers, cutters, carriers, cleavers, gardeners, soldiers, winged males, winged females, and queens, which can vary according to the species. Ants are one of the groups of insects with the greatest specific and ecological diversity in tropical latitudes, they perform important functions in all ecosystems and constitute about 15% of the total animal biomass, they have specialization in their feeding habits and close relationships with a plant (Vergara and Castrillón, 2005; Asenjo, 2018).

Most staphylinids are predators and feed on invertebrates such as nematodes, mites, springtails, and other staphylinids. They are saprophagous and utilize decaying organic matter of animal, plant, or fungal origin, while phytophagous feeding preferences represent a smaller proportion. Staphylinids are found in a wide variety of environments, especially those with high humidity. Nearly half of the species live in leaf litter and constitute one of the most common and ecologically important groups in soil fauna (García-París *et al.*, 2016; Sellen, 2017; Asenjo, 2018).

1.1. Objective

This manuscript aims to gain knowledge about the chemical composition, possible therapies, medications, and treatment of venoms from colored ants (Hymenoptera) and beetles (Coleoptera).

2.0. Methods

This is a bibliographic review of literature. Data collection was the result of a search in databases of articles that gather information in English: PubMed (<http://www.ncbi.nlm.nih.gov/pubmed>), STM (Science Translational Medicine, <https://stm.sciencemag.org>); and SciELO (Scientific Electronic Library Online, <http://www.scielo.org/php/-index.php>). For the information databases that gather works in English, together with the academic journal, the following keywords were used: Venoms, beetles, colorful ants, Coleoptera, and Hymenoptera. After screening, each manuscript was read to ensure textual quality and effectiveness.

3.0. Selected Studies

3.1. *Lytta vesicatoria* Linnaeus, 1758 (Coleoptera: Meloidae)

Holometabolous pterygote insect. Size 12-20 mm. Elongated and depressed body, metallic green in color with iridescent copper or reddish and blue reflections. Ventrally it has a coppery-red shine. Reticulate integument with thicker tips. Trapezoidal head, filiform antennae, opaque black, inserted close to the eyes, which are low-set (Figure 1) (García-París *et al.*, 2016; Sellen, 2017; Ornosá *et al.*, 2021).



Figure 1: *Lytta vesicatoria* Linnaeus, 1758 (Coleoptera: Meloidae)

Sources: Teresa Nunes -23.11.17 and <https://pontobiologia.com.br/besouros-que-soltam-acido/lytta-vesicatoria/>

Apex with a marked central groove. Transverse pronotum. Subparallel elytra of rough appearance with two marked longitudinal striae, somewhat dehiscent and rounded at the apex, completely covering the abdomen. Visible scutellum. Anterior tibiae with prominent external apical angles, in the posterior tibiae are spatula-shaped (Vieira, 2014; Sellen, 2017; Ornosá *et al.*, 2021).

Lytta vesicatoria is native to Europe, Asia Minor, and North Africa, and is usually found in warm regions, especially in deciduous forests and scrublands, where it feeds mainly on ash, olive lilac, leaves, and flower nectar (Schlager, 2004; Sellen, 2017; Ornosá *et al.*, 2021).

When the Spanish fly eggs hatch, they seek out solitary hives and infiltrate them, feeding on the eggs and the supplies of pollen and nectar they find inside. They remain there long enough until they reach adulthood and can leave the bee colony. The larvae act as parasites on another insect essential to terrestrial life (Gubler, 2010; Mercant, 2011; Ornosá *et al.*, 2021).

3.2. Cantharidin

This substance (Lactose cantharidic acid – terpenoid) is used for therapeutic anti-irritant masks, papillomas, warts, and second-degree burns. It is also used in the treatment of acute cystitis in dogs and cats. But its oldest use was as an aphrodisiac, irritating the urinary tract, nephritis, and penile erection. (Figure 2) (Schlager, 2004; Sellen, 2017; Ormosa *et al.*, 2021; Ren and Kinghorn, 2021).

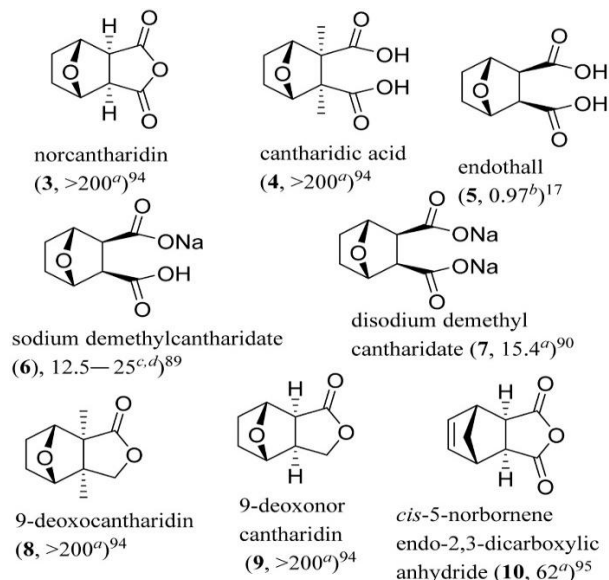


Figure 2: Structures of cantharidin derivatives (3–10) and IC₅₀ values (μM) toward the human ^aHepG2 hepatoma and ^cSMMC-7721 and ^dBel-7402 HCC cell lines and for the ^binhibition of PP2A

Source: Doi: 10.1016/j.bmc.2021.116012

Applying cantharidin to a skin lesion is usually not painful. The resulting blister can sometimes be uncomfortable. Cantharidin is extremely toxic if ingested orally. In a small number of patients, a ring of small satellite warts around an original viral wart may appear after treatment with cantharidin (Figures 3-4) (Aguirre, 2005; Aggrawal, 2007; Blood *et al.*, 2007; Dinh *et al.*, 2011; García-Paris *et al.*, 2016).

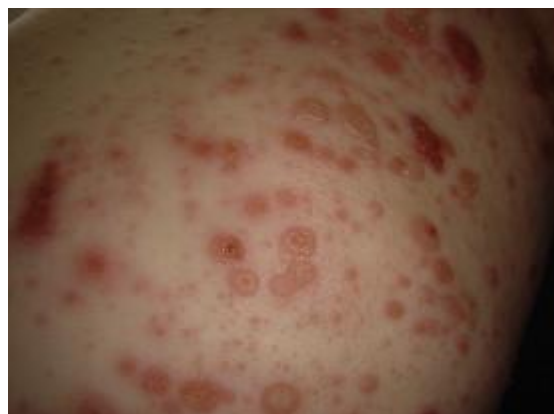

Figure 3: Varicelliform vesicular dermatitis caused by petrolatum use following cantharidin treatment of molluscum contagiosum lesions

Source: Doi:10.1016/j.jaad.2008.03.025

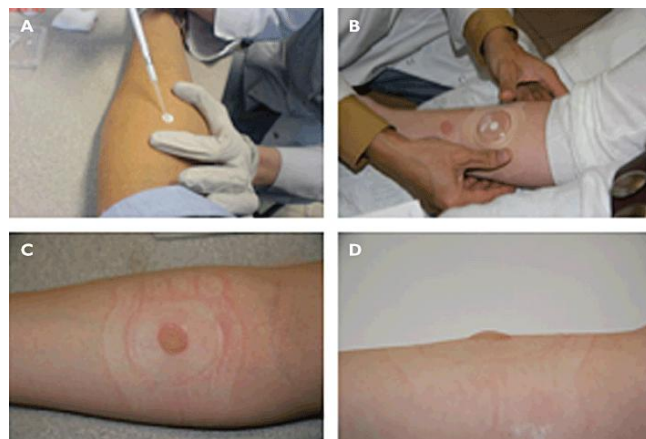


Figure 4: Cantharidin-induced blister procedure. (A) A filter paper; 25 ml of a 0.1% cantharidin solution in acetone (B) Cover with film and tape; (C) For 24 hours

Source: Doi:10.1111/j.1365-2125.2011.04020.x

Cantharidin was captured, dried, and crushed, obtaining an iridescent powder with an unpleasant odor. This powder was used as a topical medicine to treat skin diseases; it was believed that it could cure warts, herpes, or leprosy. It was also consumed orally to treat urogenital diseases due to its effect on dilating blood vessels in the genitals. Cantharidin is also a natural stimulant that aims to improve mood to help people overcome fatigue. Designed to provide an unparalleled energetic experience, Coleoptera is the perfect complement for those who want to increase their vitality and daily performance. With it, you will have a unique combination of essential nutrients (Figure 5) (Jonas, 2005; Ledermann, 2007; Gubler, 2010; Mercant, 2011; García-Paris *et al.*, 2016; Su *et al.*, 2016; Sellen, 2017; Ormosa *et al.*, 2021).

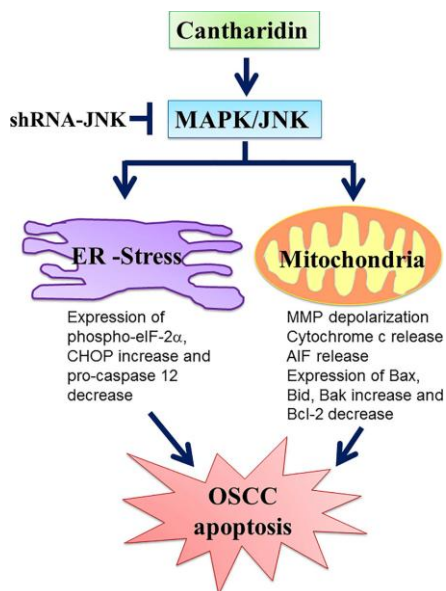


Figure 5: The schematic representation of proposed mechanisms of cantharidin on oral squamous cell carcinoma cells. Cantharidin-induced cell apoptosis via the N-terminal kinase (JNK)-regulated mitochondrial stress signaling pathways

Source: Doi: 10.1371/journal.pone.0168095.g010

3.3. *Paederus* Fabricius, 1775

Paederus Fabricius, 1775 (Coleoptera: Staphylinidae) known as potós in Brazil. These insects are nocturnal and are attracted to artificial light sources. The adult has an elongated body, predominantly black, subglobular thorax, and short elytra of bright color, the size varies between 0.5 and 50 mm, although most are between 2 and 10 mm (Amado, 2010; Gasi3n and Fern3ndez, 2013; Rakha, 2013).

Paederus can have double coloration: red and black or red and blue. Fallen leaves of plants, grass, fungi, tree bark, debris, mammal excrement, bird excrement, insect excrement, ants, beetles, bees in natural cavities, vegetation, and flowers. Most feed on plant remains or decomposed material (Amado *et al.*, 2010; Gasi3n and Fern3ndez, 2013; Rakha, 2013; Asenjo, 2018).

fly, we prefer to run and are extremely old during the day, it seems that flight is quite restricted at night. They have the characteristic habit of curling their abdomen when running or uncomfortable. The eggs are usually laid in a moist substance. The larvae develop between 3 and 19 days. Most go through three larval stages, however, in all known subfamilies, Paederinae has been reported to have two predatory larval stages (Mittal *et al.*, 2013; Fierro-Reinoso *et al.*, 2018).

Adults are nocturnal and are attracted to light. fluorescent and incandescent lamps, resulting in accidental contact with humans in their homes or buildings, such as hospitals. They can also be collected in black light and white light guns (Ahmed *et al.*, 2013; Fierro-Reinoso *et al.*, 2018).

Unlike other venomous arthropods, *Paederus* does not cause poisoning by bites or stings, but rather by contact with human skin and its hemolymph. Adults defend themselves with their jaws, trying to bite, or at the same time, they curl their abdomen up and down as a way to scare whoever attacks them. However, they do nothing, as they do not have an excretory organ, that is, they only release the toxin if you rub them (Kanamitsu and Frank, 1987; Oborski *et al.*, 2015; Suarez-Ognio *et al.*, 2015).

Pederin (C₂₅H₄₅N₉) is a crystalline amide, soluble in water and alcohol, with DNA-inhibiting action that acts at the cellular level due to mitotic blockade. Adults, eggs, and larvae of *Paederus* contain the toxin, but the dermatitis produced in females is more serious, suggesting some relationship with the female reproductive system. Two other crystalline amides, pseudopederin, and pederone, have also been isolated from the hemolymph (Figure 6) (Zahradnik and Blasco, 1990; Vieira, 2014; Oborski *et al.*, 2015; Suarez-Ognio *et al.*, 2015; Maleki-Ravasan *et al.*, 2018).

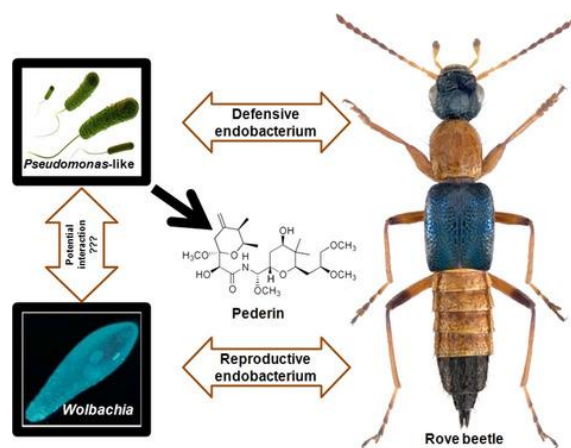


Figure 6: Co-occurrence of pederin-producing and *Wolbachia* endobacteria in *Paederus fuscipes* Curtis, 1840 (Coleoptera: Staphylinidae) and its evolutionary consequences

Source: <https://doi.org/10.1002/mbo3.777>

It is a chemical substance that, when it comes into contact with the skin, causes an inflammatory condition characterized by skin lesions, known as pederism or linear dermatitis. This reaction occurs when the person, when trying to push the beetle away, crushes it against the skin, spreading the toxin. The resulting lesions resemble chemical burns and evolve from erythema to the formation of blisters and can take weeks to heal (Todd *et al.*, 1996; Pagottoa *et al.*, 2013).

The lesion is characterized by caustic dermatitis bullous lesions, produced by a toxic crystalline substance called pandering, capable of blocking cellular mitotic activity and DNA synthesis, causing erythema, epidermal necrosis, and vesiculation (Oborski *et al.*, 2015; Fierro-Reinoso *et al.*, 2018).

3.4. Histopathological studies describe four stages:

1. Onset: first 24 to 48 hours characterized by edema, erythema, pruritus and sometimes papules.
2. Evolution: vesicles form after 48 hours. Between the fifth and eighth day, the toxin spreads and gives rise to.
3. Secondary lesions around the primary lesion. At this stage, there may be pain, fever, and general malaise.
4. Regression: After 8 days, the erythema diminishes and scabs' form.
5. Total regeneration: the scab has reduced in size and eventually falls off for 20 and 35 days. It leaves no scar, only residual hyperpigmentation that later disappears (Pagottoa *et al.*, 2013; Suarez-Ognio *et al.*, 2015; Fierro-Reinoso *et al.*, 2018).

Numerous outbreaks of dermatitis caused by beetles of the *Paederus* species have been described worldwide. They are distributed throughout the world, except in Antarctica; neighboring countries such as Brazil, Argentina, Ecuador, Panama, and Venezuela have also

reported dermatitis caused by *Paederus* (Kanamitsu and Frank, 1987; Gasi3n and Fern3ndez, 2013; Mittal *et al.*, 2013).

The venom of the *Paederus* beetle can be used to treat cancer. "The venom shows an adverse effect on cancer cells. Our team and the colleagues we work with abroad are working with the venom," [Dr. Sinan Anlas - Anadolu Agency 2018]. However, the species of this genus that causes the most problems is *P. irritans*, found in South American countries such as Peru and Ecuador. It causes significant skin lesions. High temperatures and high humidity caused by heavy rains accelerate their reproduction (Todd *et al.*, 1996; Mittal *et al.*, 2013; Suarez-Ognio *et al.*, 2015).

Characteristics of dermatitis caused by the species *Paederus irritans*, (Linnaeus, 1758), known as yuyi, or zorrito. It has an elongated body, a general black color, a subglobular thorax, short elytra, and a very bright dark blue color. These insects are frequently found in the vegetation of valleys located between 600 and 900 meters above sea level, on the northern coast of Peru. These areas have high humidity and large temperature fluctuations during the day and at night (Pagottoa *et al.*, 2013; Oborski *et al.*, 2015; Fierro-Reinoso *et al.*, 2018).

4.0. Ants Color (Hymenoptera: Formicidae)

Ants vary in color, most ants are yellow to red or brown to black, but some species are green, and some tropical species have a metallic sheen. Imported fire ants live in colonies in the southeastern and southwestern United States. They first make a nest in the ground and then form a mound of dirt on top of it. These mounds can be up to 18 inches, 46 cm long, and 24 inches 60 cm wide. author. Imported fire ant nests can be found in lawns, parks, playgrounds, and fields. Some imported fire ants make their nests in the walls of buildings (Figure 7) (Bolico *et al.*, 2012; Buttaravoli *et al.*, 2022).

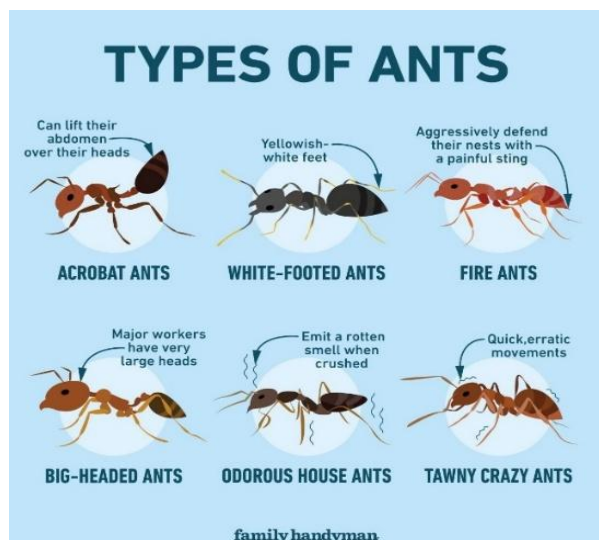


Figure 7: Some colorful ants

Source: Gemma Johnstone and <https://www.familyhandyman.com/list/how-to-identify-types-of-ants/>

Ants build their earthen nests in the ground, usually on the edges of sidewalks or streets. In dry, sandy soils, the mounds can be completely flat. Since fire ants do not remove vegetation from the area around their mounds, they can be difficult to see. Fire ants bite with their mandibles as they sting. This allows them to withdraw the stinger, rotate it, and sting again. A single ant can inflict multiple stings in a very short time. A fire ant will attach itself to a person by biting them with its mandibles. It will then rotate its head and sting from the abdomen in a circular pattern in several places (Delabie *et al.*, 2009; Curtis and Erickson, 2023).

They look like wingless wasps, but very few have stingers, except for the red fire ant. If you look closely at an ant's body, you'll also see one or two bumps in the thin area between the last two segments. In addition, the antennae have a bend. When a fire ant stings a person, they feel a sharp, burning pain. If a person steps on a pile of fire ants, they will receive several stings at once because their habitat has been disturbed. The next day, each sting will turn into an itchy blister. Sometimes, an allergic reaction similar to that caused by a bee sting can occur, with breathing problems or tightness in the chest or throat (Fern3ndez and Sendoya, 2004; Elston, 2018; Rabelo, 2020).

Symptoms of fire ant stings may include Swelling, redness, itching, and pain around the sting site. Pus-filled blisters that last 3 to 8 days. Possible scabbing at the sting site that lasts 3 to 10 days. People who are allergic to fire venom may also experience: Difficulty breathing. Rapid heart rate. Swelling of the throat. Multiple fire ant stings can cause vomiting, diarrhea, swelling throughout the body, difficulty breathing, low blood pressure, rapid heart rate, and shock. (Santos and Mayh3-Nunes, 2007; Erickson and M3rquez, 2017; Rabelo, 2020).

4.1. Reaction to sting:

- A. Severe, life-threatening allergic response is called anaphylaxis.
- B. The main symptoms are hives with difficulty breathing and swallowing. It begins within 2 hours of the sting.
- C. This severe reaction to fire ant stings occurs in 1% to 2% of children.
- D. Hives. After fire ant stings, some children simply develop hives all over their bodies or swelling on their faces. However, these symptoms can sometimes lead to anaphylaxis (Figure 8) (Kundrotas, 1993; Elston, 2018; Rabelo, 2020; Curtis and Erickson, 2023).

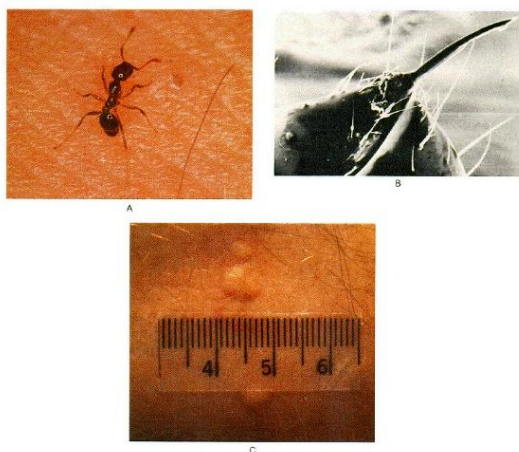


Figure 8: Sting of the fire ant *Solenopsis* Westwood, 1840

Source: Doi: 10.1056/NEJM199310283291806

The ant venom can kill bacteria and some skin cells. This produces a blister that fills with cloudy white material within about 24 hours. Although it looks like a pus-filled lesion that needs to be drained, it is sterile and will heal faster if left untreated. The toxic element: The venom of red ants contains a chemical called piperidine. It is an organic compound with the formula $C_5H_{11}N$. It is a heterocyclic amine with a six-membered ring containing five carbon atoms and one nitrogen atom (Figure 9) (Sá *et al.*, 2009; Atal and Bedi, 2010; Singletary, 2010; Park, *et al.*, 2012; Jayan, 2023).

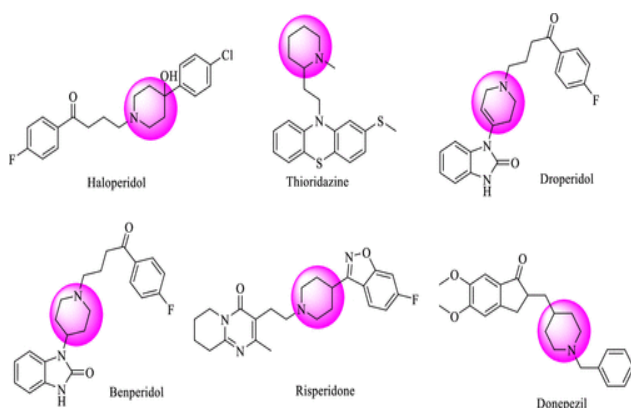


Figure 9: Structures of FDA-approved drugs containing a piperidine nucleus

Source: Doi: 10.1021/acsomega3c05719

The basic structure of piperidine is present in several natural alkaloids, such as quinine and piperine, the main chemical agent in black pepper and its relatives in the *Piper* L. (Piperoidae), hence its name. Piperidine is also found in the venom of fire ants and is responsible for the burning sensation associated with the bites of these insects. They are salts derived from hydrogen cyanide (HCN), also called hydrocyanic acid or prussic acid. Both salts and acids are known to be highly lethal, causing almost immediate death (Figure 10) (Sá *et al.*, 2009; Atal and Bedi, 2010; Singletary, 2010; Park *et al.*, 2012; Mitra *et al.*, 2022).

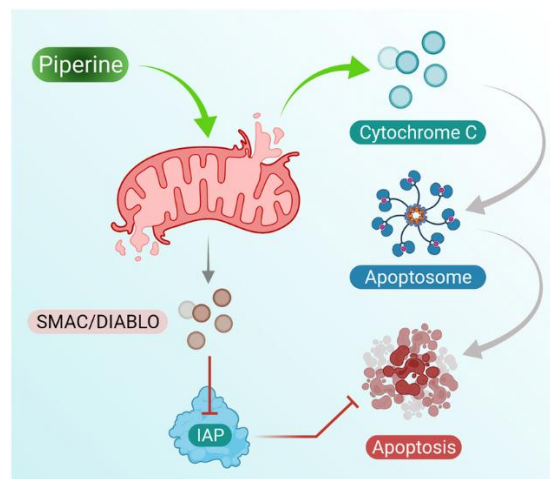


Figure 10: Piperine treatment mediates cytochrome c secretion (activates apoptosome formation) and mitochondrial SMAC/DIABLO, which suppresses IAP activity and inhibits cell apoptosis; these induce cell apoptosis in breast cancer cells

Source: Doi: 10.3389/fphar.2021.772418

For severe allergies, carry an epinephrine auto-injector or epinephrine nasal spray if necessary. Learn how to administer epinephrine and replace the product before the expiration date indicated on the label. Remember that epinephrine is only a rescue medication: you should still go to the emergency room immediately if you have been stung by an insect. Give acetaminophen or ibuprofen for pain relief. For itching, give an oral antihistamine and apply a corticosteroid cream or calamine lotion to the bite area (Erickson *et al.*, 2017; Elston, 2018; INPE, 2018; Rabelo, 2020; Curtis and Erickson, 2023).

4.2. Chemical Substances/ Piperine

- Piperine is an alkaloid extracted from black pepper seeds. It is a natural stimulant that interferes with the absorption of selenium, vitamin B, and B-carotene.
- Piperine is used in folk medicine to treat digestive problems such as constipation, diarrhea, and indigestion, but also in cases of joint pain, heart disease, angina, and gangrene.
- Piperine is a lipophilic alkaloid capable of stimulating the biosynthesis of serotonin in the Central Nervous System. It can also be used as an insecticide.
- Among its biological activities, piperine has antimicrobial, anti-inflammatory, and antiparasitic activity against Chagas disease and leishmaniasis, and antioxidant properties.
- They enable the creation of complex molecules and serve as building blocks for agrochemicals, catalysts, and materials science.
- They can explore new methods of pollutant degradation and environmental restoration, helping to address urgent ecological challenges.
- Piperidines are studied for their interactions with enzymes and proteins, providing information on fundamental biological processes and aiding in

the design of biochemical assays (Figures 11-12) (Sá *et al.*, 2009; Atal and Bedi, 2010; Singletary, 2010; Park, *et al.*, 2012).

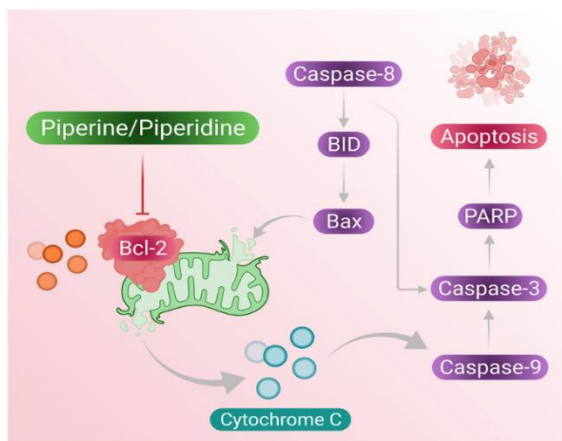


Figure 11: Piperine and piperidine-induced caspase pathway for activating cell apoptosis in cancer cells

Source: Doi: 10.3389/fphar.2021.772418

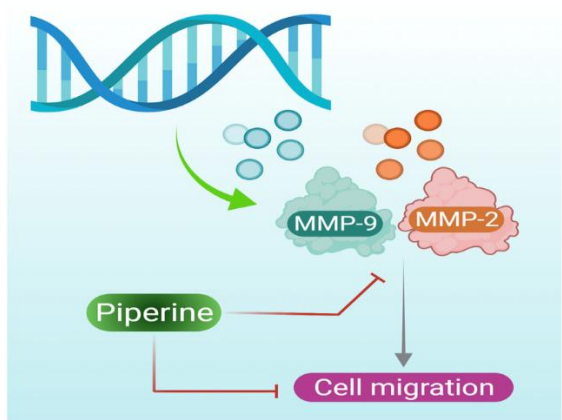


Figure 12: Piperine inhibits the expression of the MMP-2 and MMP-9 genes, further reducing the cell migration of breast cancer cells

Source: Doi: 10.3389/fphar.2021.772418

4.3. Some Species

Monomorium pharaonis (Linnaeus, 1758) (Hymenoptera: Formicidae).

Pharaoh ant workers have a nonfunctional stinger used to generate pheromones. They do not form swarms; mating occurs in the nest. They are light yellow to reddish brown with a darker shade on the abdomen. The pharaoh and queen can lay hundreds of eggs during her lifetime (Hoelldobler and Wilson, 1990).

From 10 to 12 eggs per batch in the first few days of egg production and only four to seven eggs per subsequent batch. The eggs hatch in five to seven days. The larval period is 18 to 19 days, the prepupal period is three days, and the pupal period is nine days (Hoelldobler and Wilson, 1990; Manami *et al.*, 2012).

Linepithema humile (Mayr, 1868) (Hymenoptera: Formicidae).

Fire ant workers attach themselves to the skin with their mandibles and then lower the tip of their gaster to inject

their stinger into the victim. Fire ants therefore sting and bite, but only the sting is responsible for the pain and the pustule (De Biseau *et al.*, 2004).

Minor workers can live from 30 to 60 days, intermediate workers from 60 to 90 days, major workers from 90 to 180 days, and queens can live from two to six years. The complete life cycle, from egg to adult, takes between 22 and 38 days (De Biseau *et al.*, 2004).

Solenopsis spp. (Hymenoptera: Formicidae)

Red to brown with black gaster. They form exams. Fire ant workers attach themselves to the skin with their mandibles and then lower themselves to the tip of the gaster to inject the sting into the victim. Therefore, fire ants bite and sting, but only the bite is responsible for the scaling and peeling of the pustule (Santos and Mayhê-Nunes, 2007).

Smaller workers can live from 30 to 60 days, intermediate workers from 60 to 90 days, larger workers from 90 to 180 days, and the rain ants can live from two to six years. The complete life cycle, from egg to adult, takes between 22 and 38 days. Mating occurs during flight and males die after mating with females (Erickson *et al.*, 2017).

5.0. Conclusion

Currently, cantharidin topographic products do not necessarily demonstrate better efficacy in the treatment of cancer. Pederin production has been shown to depend on the activities of an endosymbiont *Pseudomonas* ssp. within *Paederus*. Pederin is a toxin present in the hemolymph of some beetles of the genus *Paederus*, popularly known as potôs. It is the main cause of pederism dermatitis, an inflammatory reaction that causes skin lesions. The broad applicability and unique reactivity of piperidine make them indispensable tools for driving innovation and expanding our understanding of chemical and biological systems. Their role in multiple disciplines underscores this therapeutic effect of promoting effective action on the immune system, as in the case of diseases that lead to immunosuppression, such as chemotherapy and radiotherapy in the treatment of cancer.

References

1. Aggrawal, A. (2014). APC Textbook of Forensic Medicine and Toxicology-Avichal Publishing Company. Avichal publishing company.
2. Aguirre, R. D. (2005). Informal empire: Mexico and central america in victorian culture.
3. Ahmed, M. S., Boraei, H. A., & Rakha, O. M. (2013). Histopathological characterization of induced *Paederus dermatitis* caused by Egyptian rove beetles (*Paederus alfieri*). *Beni-Suef University Journal of Basic and Applied Sciences*, 2(2), 108-113.
4. Amado, R. C., Rabelo, J. V. C., Braga, P. M. F., & Chumbinho, S. D. A. (2010). Identificação de surto de dermatite causada por besouro potô (*Paederus brasiliensis*) em Betim, Minas Gerais,

2009. *Epidemiologia e Serviços de Saúde*, 19(4), 403-405.
5. Asenjo, A., Klimaszewski, J., Chandler, D. S., Fierros-López, H. E., & Vieira, J. S. (2019). Staphylinidae (Insecta: Coleoptera) in Latin America: synopsis, annotated catalog, diversity and distribution. *Zootaxa*, 4621(1), 1-406.
 6. Atal, N., & Bedi, K. (2010). Bioenhancers: Revolutionary concept to market. *Journal of Ayurveda and integrative medicine*, 1(2), 96.
 7. Whitman, D. W., Andrés, M. F., Martínez-Díaz, R. A., Ibáñez-Escribano, A., Olmeda, A. S., & González-Coloma, A. (2019). Antiparasitic properties of cantharidin and the blister beetle *Berberomeloe majalis* (Coleoptera: Meloidae). *Toxins*, 11(4), 234.
 8. Bolico, C. F., Olivera, E. A., Gantes, M. L., Dumont, L. F. C., Carrasco, D. S., & D'Incao, F. (2012). Myrmecofauna (Hymenoptera, Formicidae) of two Marshes of the Lagoa dos Patos Estuary, RS: Diversity, fluctuation, abundance and similarity as conservation indicators. *EmtoBrasilis*, 5(1), 11-20.
 9. Buttaravoli, P. M., Leffler, S., Herrington, R. R. (2022). Fire ant stings. In P. M. Buttaravoli, S. Leffler, R. R. Herrington. (Eds), *Minor emergencies*. (pp. 1-169). Philadelphia: Elsevier.
 10. Curtis, A. M., & Erickson, T. B. (2023). Venomous animal injuries. *Rosen's Emergency Medicine: Concepts and Clinical Practice*. 10th ed. Philadelphia, PA: Elsevier.
 11. de Biseau, J. C., Passera, L., Daloze, D., & Aron, S. (2004). Ovarian activity correlates with extreme changes in cuticular hydrocarbon profile in the highly polygynous ant, *Linepithema humile*. *Journal of Insect Physiology*, 50(7), 585-593.
 12. Delabie, J. H., Céréghino, R., Groc, S., Dejean, A., Gibernau, M., Corbara, B., & Dejean, A. (2009). Ants as biological indicators of Wayana Amerindian land use in French Guiana. *Comptes rendus biologies*, 332(7), 673-684.
 13. Dinh, P. H. D., Corraza, F., Mestdagh, K., Kassenger, Z., Doyen, V., & Michel, O. (2011). Validation of the cantharidin-induced skin blister as an in vivo model of inflammation. *British journal of clinical pharmacology*, 72(6), 912-920.
 14. Elston, D. M. (2018). Bites and stings. In J. L. Bologna, J. V. Schaffer, L. Cerroni. (Eds), *Dermatology*. (pp. 1-85). Philadelphia, Elsevier.
 15. Erickson, T. B., & Cheema, N. (2017). Arthropod Envenomation in North America. *Emergency Medicine Clinics*, 35(2), 355-375.
 16. Fernández, F., & Sendoya, S. (2004). List of neotropical ants (Hymenoptera: Formicidae). *Biota Colombiana*, 5(1), 3-93.
 17. Fierro-Reinoso, M., Rios-Araujo, A., & Jhonston, E. (2018). *Paederus* sp. dermatitis in the Peruvian Amazon: Case report. *Annals of the Faculty of Medicine*, 79(1), 49-52.
 18. García-París, M., José, L., Ruiz, J. L., Daniel, N. P., & Buckley, D. (2016). Common names of cantharides and oilworms (Coleoptera: Meloidae) from Spain: circumstances dictate. *Bulletin of the Aragonesa Entomological Society (S.E.A.)*, 58, 245-252.
 19. Gasi6n, F. B., & Fernández, M. A. R. (2013). Clinical toxicology. injuries from animal bites and stings. Madrid: Bubok Publishing SL.
 20. Gubler, R. (2010). 18th-century Yucatecan herbal sources. The very safe book of medicines and Medicine notebook. Mérida: CephcisUnam. 2010.
 21. Hölldobler, B., & Wilson, E. O. (1990). The ants. Harvard University Press.
 22. Jayan, J., Chandran, N., Thekkantavida, A. C., Abdelgawad, M. A., Ghoneim, M. M., Shaker, M. E., ... & Mathew, B. (2023). Piperidine: a versatile heterocyclic ring for developing monoamine oxidase inhibitors. *ACS omega*, 8(41), 37731-37751.
 23. Jonas, W. B. (2005). *Mosby's dictionary of complementary & alternative medicine*. Amsterdam: Elsevier.
 24. Frank, J. H., & Kanamitsu, K. (1987). *Paederus*, sensu lato (Coleoptera: Staphylinidae): natural history and Medical Importance. *Journal of medical entomology*, 24(2), 155-191.
 25. Kundrotas, L. (1993). Sting of the fire ant (*Solenopsis*). *New England Journal of Medicine*, 329(18), 1317-1317.
 26. Ledermann, W. D. (2007). Sim6n Bolívar and the Cantharides. *Chilean Journal of Infectology*, 24(5), 409-412.
 27. Maleki-Ravasan, N., Akhavan, N., Raz, A., Jafari, M., Zakeri, S., & Dinparast Djadid, N. (2019). Co-occurrence of pederin-producing and *Wolbachia* endobacteria in *Paederus fuscipes* Curtis, 1840 (Coleoptera: Staphylinidae) and its evolutionary consequences. *MicrobiologyOpen*, 8(7), e00777.
 28. Mamani-Mamani, B., Loza-Murguía, M., Smeltekop, H., Almanz, J. C., & Limachi, M. (2012). Genetic diversity of ants (Hymenoptera: Formicidae) in forest sets, forest borders, and areas cultivated in three Communities in the Municipality of Coripata, Nor Yungas Department of La Paz, Bolivia. *Journal of the Andean Forest Research Society*, 1(1), 26-43.
 29. Mercant, J. (2011). Contribution to the history of urological pharmacotherapy. *Actas Urol6gicas Españolas (English Edition)*, 35(2), 99-106.
 30. Mitra, S., Anand, U., Jha, N. K., Shekhawat, M. S., Saha, S. C., Nongdam, P., ... & Dey, A. (2022). Anticancer applications and pharmacological properties of piperidine and piperine: a comprehensive review on molecular mechanisms and therapeutic perspectives. *Frontiers in Pharmacology*, 12, 772418.
 31. Mittal, A., Mehta, S., Garg, A., Gupta, L., Kuldeep, C. M., Khare, A. K., & Nistha, S. (2013). Beetle dermatitis is a common condition seen in

- regions with warm and tropical climate. The condition causes significant morbidity and can be misdiagnosed: Hanoy: Scoop.
32. Oborski, M. R., Capelli, L., Montardit, A. L., Carabajal, G., & Mazzini, M. A. (2015). Dermatitis por contacto por *Paederus*. *Dermatología Argentina*, 21(1), 56-58.
 33. Ornosá, C., Tello, A., & Romero, D. (2021). Analysis of the situation and proposals for the conservation of insects. Madrid: Ecologists in Action.
 34. Pagottoa, B. et al. (2013). *Paederus* contact dermatitis in a 12-year-old boy. *Argentine Archives of Pediatrics*, 111(3), e66-e68.
 35. Park UiHyun, P. U., Jeong HongSuk, J. H., Jo EunYoung, J. E., Park TaeSun, P. T., Yoon SeungKew, Y. S., Kim EunJoo, K. E., ... & Um SooJong, U. S. (2012). Piperine, a component of black pepper, inhibits adipogenesis by antagonizing PPAR γ activity in 3T3-L1 cells. *Journal of Agricultural and Food*, 60(15), 3853-60.
 36. Ren, Y., & Kinghorn, A. D. (2021). Antitumor potential of the protein phosphatase inhibitor, cantharidin, and selected derivatives. *Bioorganic & medicinal chemistry*, 32, 116012.
 37. Sa, J. L. S., Vieira, L. H., & Lima-Neto, B. S. (2009). Piperidine and peridro azepine as ancillary ligand versatile in catalytic activity of complexes type [RuCl₂(PPH₃)₂L] in polymerization by metathesis; Piperidina e peridroazepina como versateis ligantes ancilares na atividade catalitica de complexos do tipo [RuCl₂(PPh₃)₂L] em polimerizacao via metatase. Retrieved Mar,10, from <https://www.osti.gov/etdeweb/biblio/21295080>
 38. Muluvhahothé, M. M. (2018). A functional and trait-based approach in understanding ant community assembly in the Soutpansberg Mountains, South Africa (Doctoral dissertation). Retrieved Mar, 20, 2025, from chrome-extension://efaidnbmnnpicajpcglclefindmkaj/<https://univendspace.univen.ac.za/server/api/core/bitstreams/488f32f3-98fa-4796-b526-eff4b59fcc28/content>
 39. Schlager, N., & Murphy, J. B. (2003). *Grzimek's animal life encyclopedia*. Gale.
 40. Sellen, A. T. (2017). "Mexican Cantharides": A Source for the History of Natural Medicine. *Relaciones. Estudios de historia y sociedad*, 38(151), 161-191.
 41. Singletary, K. (2010). Black pepper: overview of health benefits. *Nutrition Today*, 45(1), 43-47.
 42. Grelle, C. E., Bayma, A. P., Paixão, L. R. L., Egler, M., Senta, M. M. D., Jenkins, C. N., ... & Vieira, M. V. (2021). Conservation initiatives in the Brazilian Atlantic forest. *The Atlantic Forest: history, biodiversity, threats and opportunities of the mega-diverse forest*, New York: Springer, Cham.
 43. Su, C. C., Lee, K. I., Chen, M. K., Kuo, C. Y., Tang, C. H., & Liu, S. H. (2016). Cantharidin induced oral squamous cell carcinoma cell apoptosis via the JNK-regulated mitochondria and endoplasmic reticulum stress-related signaling pathways. *PLoS one*, 11(12), e0168095.
 44. Suarez-Ognio, L., Estela-Ayamamani, D., Cáceres-Mejía, B., Gambirazio-Carbajal, C., & Cabrera, R. (2015). Impact of the "El Niño" phenomenon from 1997 to 1998 on the health of the Peruvian population: risk potential for 2015. *Revista Peruana de Medicina Experimental y Salud Publica*, 32(2), 403-404.
 45. Todd, R. E., Guthridge, S. L., & Montgomery, B. L. (1996). Evacuation of an Aboriginal community in response to an outbreak of blistering dermatitis induced by a beetle (*Paederus australis*). *Medical journal of Australia*, 164(4), 238-240.
 46. Todd, R. E., Guthridge, S. L., & Montgomery, B. L. (1996). Evacuation of an Aboriginal community in response to an outbreak of blistering dermatitis induced by a beetle (*Paederus australis*). *Medical journal of Australia*, 164(4), 238-240.
 47. Zahradnik, J., & Blasco, A. (1990). Guide to the Coleoptera of Spain and Europe. Barcelona: Ediciones Omega.